SPONSORED BY UNITED MEDICAL IMAGING HEALTHCARE

Osteopoikilosis of the Knee Joint Associated with Calcific Tendinitis of Patellar Tendon [CASE STUDY]

Parvaneh Hassani, M.D., & Jamshid Tehranzadeh, MD
April 28, 2023

INTRODUCTION

Osteopoikilosis (OPK) is a rare inherited bone condition that is transmitted as an autosomal dominant trait or, in some cases, sporadic[1,2]. It is usually asymptomatic and is often discovered by chance during routine radiographs. The patient's imaging shows numerous focal hyperostotic areas (bone islands) that tend to be located in periarticular osseous regions. In most cases, OPK can be seen on a simple radiograph, but further imaging such as CT or MRI can reveal dense radio-opaque spots[4,5].

The metaphysis and epiphysis of long bones are where the majority of the osteosclerotic lesions are found, mainly in and around the joint. It's critical to differentiate OPK from malignancy because the differential diagnosis includes osteoblastic bone metastasis, tuberous sclerosis, mastocytosis, melorheostosis, and osteopathic striata[5, 6, and 7].

This Case is presenting a 64-year-old man who has right knee pain, weakness, and buckling. The patient was prescribed nonsteroidal anti-inflammatory drugs (NSAID), which were ineffective. An AP and lateral radiograph of the right knee revealed multiple hyperostotic areas in the distal femur near the proximal tibia at the level of the patella associated calcific tendinitis of patellar tendon.

CASE PRESENTATION

A 64-year-old man was brought to the clinic by the chief complaint of knee pain, weakness, and buckling of the right knee. The plain radiograph revealed multiple bone islands at the vicinity of the knee joint at distal femur and proximal tibia as well as calcification/ ossification of the patellar tendon. MRI revealed the same focal low signal foci of osteosclerosis in the periarticular areas of knee joint associated with thickening of the patellar tendon suggesting chronic tendintis. (Figures 1 & 2)

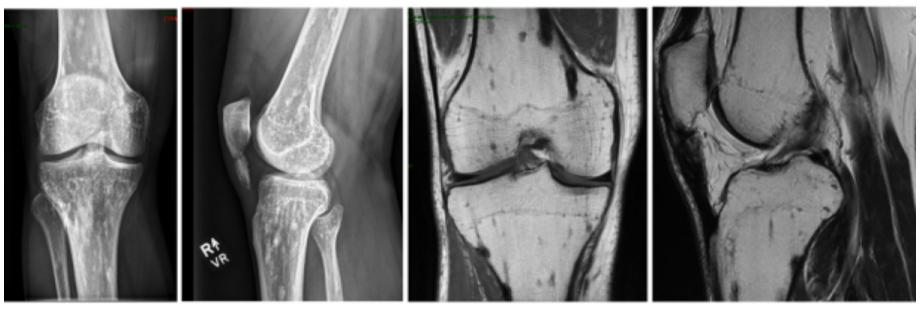

Figure 1A Figure 1B Figure 2A Figure 2B

DISCUSSION

Osteopoikilosis, also known as "spotted bone disease," is a rare benign sclerotic osteodysplasia with an autosomal dominant hereditary pattern that can be detected incidentally during imaging for other reasons[8]. OPK is thought to be caused by a mutation in the LEMD3 gene, which produces a protein that aids in bone formation. the mutation of LEMD3 gene results in insufficient protein and excessive bone tissue[9].

Genetic studies have revealed that LEMD3 encodes an inner nuclear membrane protein that inhibits the bone morphogenic proteins (BMPs) and transforming growth factor (TGF)-beta signaling pathways via interactions with specific SMAD family proteins. Loss-of-function mutations in LEMD3 cause upregulation of downstream targets in both pathways, resulting in altered fibroblast function and increased bone formation[10]. Fibroblasts in affected patients produce more trophoblastic and elastin as a result of increased TGF-beta and BMP signaling, resulting in the distinctive cutaneous phenotype[11,12].

The estimated incidence of OPK is 1:50,000, and it can affect anyone between the ages of 15 and 60. The ratio of males to females is 3:2[13].

Despite the fact that OPK is typically asymptomatic, about 20% of patients have been reported to experience some degree of articular pain or joint effusion[14], as in this case where the patient initially complained of right knee pain.

Osteopoikilosis does not progress to malignancy or weaken the bones, so there is no specific treatment for OPK other than patient education and reassurance. NSAIDs may be used to treat pain if necessary. This diagnosis should be kept in mind at all times in order to avoid unnecessary and costly investigations[15].

Differential diagnosis of OPK based on imaging characteristics includes

- Osteopathic Striata (e.g., sclerotic pattern is linear)
- Melorheostosis (e.g., sclerotic pattern mimic "candle wax "appearance)
- Tuberous Sclerosis (e.g., more diffuse bone islands through the skeleton)
- Sclerotic bone metastases.
- Osteomas (e.g., often large sclerotic pattern associated with Gardner syndrome) which may have similar clinical pictures, but those may require orthopedic treatment.

In patients with characteristic clinical and radiologic findings, genetic testing is not routinely performed to confirm the diagnosis of OPK. If the diagnosis is unclear, genetic testing for germline mutations in the LEMD3 gene may be useful in confirming the diagnosis and distinguishing OPK from other conditions associated with connective tissue nevi or sclerotic bone lesions.

Osteopoikilosis may be associated with a rare skin condition called Buschke-Ollendorff syndrome which is characterized by skin growth called connective tissue nevi which is a rare autosomal dominant disorder with high penetrance and variable expressions in which sclerotic bone lesions are associated with connective tissue nevi, elastomas and collagenomas[1. 2, 17 and 18].

CONCLUSION

Osteopoikilosis (OPK) is an uncommon, rare inherited bone condition that is characterized by numerous hyperostotic foci that tend to localize in periarticular osseous regions. It is usually asymptomatic and is often discovered by chance during routine radiographs. We are reporting a 64 years old man who initially presented with chief complain of right knee pain. Plain radiograph and MRI showed multiple hyperdense spots near the joint, associated with calcification/ ossification of patellar tendon typical for Osteopoikilosis with calcific tendinitis.

Learn More

Written by:

Parvaneh Hassani, M.D., Research Fellow of Department of Diagnostic Radiology, University of Maryland

Jamshid Tehranzadeh, M.D., Chief Radiologist at United Medical Imaging Health, Professor Emeritus at University of California (Irvine)

Correspondence:

Jamshid Tehranzadeh, M.D., Chief Radiologist at UMIH, Professor Emeritus at UCI

Contact Information:

- Main Office: 323-556-3000
- Fax: 323-556-3012
- Cell: 714-272-4045
- E-mail: jtehranzadeh@umih.com

Figure Details:

Figure 1A: Osteopoikilosis: Sixty four year old man with knee pain: AP Radiograph of the knee shows multiple osteosclerotic foci at distal femur and proximal tibia associated with calcific/ossific tendinitis of the origin of the patellar tendon.

Figure 1B: Osteopoikilosis: Sixty four year old man with knee pain: Lateral Radiograph of the knee shows multiple osteosclerotic foci at distal femur and proximal tibia associated with calcific/ossific tendinitis of the origin of the patellar tendon.

Figure 2A: Osteopoikilosis: Sixty four year old man with knee pain: Coronal T1WI: shows foci of low signal in distal femur and proximal tibia representing osteosclerotic areas in the bone.

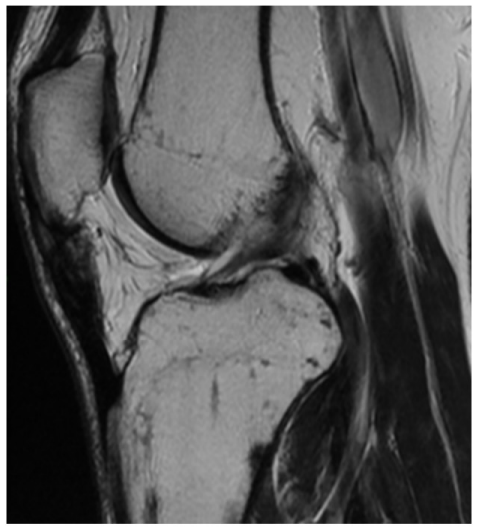

Figure 2B: Osteopoikilosis: Sixty four year old man with knee pain: Sagittal T1WI: shows foci of low signal in distal femur and proximal tibia representing osteosclerotic areas in the bone. Note thickening of patellar tendon indicating chronic tendintis.

References:

1. Mahbouba J, Mondher G, Amira M, Walid M, Naceur B, Mahbouba J. Case Report Osteopoikilosis: A rare cause of bone pain.

2. Erhan A, Burcu O•, Cakit D, Hatice •, Erdem R, Koc B. A rare benign disorder mimicking metastasis on radiographic examination: a case report of osteopoikilosis.

3. Jain A, Selvam P, Atwal H, Atwal PS. A Report of a Novel Pathogenic Variant in a Family with Buschke-Ollendorf Syndrome. J Pediatr Genet [Internet]. 2020 [cited 2023 Feb 11];9:63–5. Available from: https://doi.org/

4. Watts J, Box G, Galvin A, Brotchie P, Trost N, Sutherland T. Magnetic resonance imaging of meningiomas: a pictorial review.

5. Gnoli M, Lodewijk Staals E, Campanacci L, Francesca Bedeschi M, Faletra F, Gallone S, et al. Melorheostosis and Osteopoikilosis Clinical and Molecular Description of an Italian Case Series. Calcif Tissue Int [Internet]. 2019 [cited 2023 Feb 12];105:215–21. Available from: https://doi.org/10.1007/s00223-019-00565-6

6. Woyciechowsky TG, Monticielo MR, Keiserman B, Monticielo OA. Osteopoikilosis: What does the rheumatologist must know about it? Clin Rheumatol [Internet]. 2012 Apr [cited 2023 Feb 12];31(4):745–8. Available from: https://www.researchgate.net/publication/221748713_Osteopoikilosis_What_does_the_rheumatologist_must_know_about_it

7. Pj Verkleij S, Luijsterburg AJ, Willemsen SP, Koes BW, Bohnen AM, Ma Bierma-Zeinstra S. Effectiveness of diclofenac versus paracetamol in knee osteoarthritis: a randomised controlled trial in primary care. Research e530 British Journal of General Practice. 2015;

8. Aghdashi MA, Aghdashi MM, Rabiepoor M. Osteopoikilosis: pain as a presenting symptom in Three Family Members. Clin Med Insights Arthritis Musculoskelet Disord [Internet]. 2011 [cited 2023 Feb 12];(4):29–32. Available from: http://www.la-press.com.

9. Baasanjav S, Jamsheer A, Kolanczyk M, Horn D, Latos T, Hoffmann K, et al. Osteopoikilosis and multiple exostoses caused by novel mutations in LEMD3 and EXT1 genes respectively-coincidence within one family. BMC Med Genet [Internet]. 2010 [cited 2023 Feb 12];11:110. Available from: http://www.biomedcentral.com/1471-2350/11/110

10. Korman B, Wei J, Laumann A, Ferguson P, Varga J. Case Report Mutation in LEMD3 (Man1) Associated with Osteopoikilosis and Late-Onset Generalized Morphea: A New Buschke-Ollendorf Syndrome Variant. 2016 [cited 2023 Feb 12]; Available from: http://dx.doi.org/10.1155/2016/2483041

11. Wu M, Chen G, Li YP. TGF-β and BMP signaling in osteoblast, skeletal development, and bone formation, homeostasis and disease. Bone Res [Internet]. 2016 [cited 2023 Feb 12];4. Available from: www.nature.com/boneres

12. Wang X, Cao X. TGF-β and Genetic Skeletal Diseases. Encyclopedia of Bone Biology. 2020 Jan 1;513–20.

13. Borman P, Özoran K, Aydoğ Ş, Coşkun S. Osteopoikilosis: Report of a clinical case and review of the literature. Joint Bone Spine. 2002;69(2):230–3.

14. Learning Point of the Article. [cited 2023 Feb 12]; Available from: www.jocr.co.in

15. Aghdashi MA, Aghdashi MM, Rabiepoor M. Osteopoikilosis: pain as a presenting symptom in Three Family Members. Clin Med Insights Arthritis Musculoskelet Disord [Internet]. 2011 [cited 2023 Feb 12];(4):29–32. Available from: http://www.la-press.com.

16. Panchal SR, Gawhale S, Shah NZ, Mohanty T. Case Report of Osteopoikilosis: Sparse Cause of Bone Pain and Mimicker of Metastasis on Radiographs. J Orthop Case Rep. 2021 Mar 10;11(3).

17. Wordsworth P, Chan M. Melorheostosis and Osteopoikilosis: A Review of Clinical Features and Pathogenesis. Calcif Tissue Int [Internet]. 1234 [cited 2023 Feb 12];104:530–43. Available from: https://doi.org/10.1007/s00223-019-00543-y

18. Osteonecrosis, Osteosclerosis/Hyperostosis, and Other Disorders of Bone - ClinicalKey [Internet]. [cited 2023 Feb 12]. Available from: https://www.clinicalkey.com/#!/content/book/3-s2.0-B9780323532662002344

Comment or add others with @

© 2023 Doximity, Inc. Help Blog About Us Contact Terms of Service Privacy Community Guidelines Directory

Captured by FireShot Pro: 28 August 2023, 13:45:33
https://getfireshot.com