SPONSORED BY UNITED MEDICAL IMAGING HEALTHCARE

Case Study: Diagnosing Hydroxyapatite Deposition Disease with a Rare Manifestation of Enthesopathy at Insertion Site

United Medical Imaging Healthcare
October 20, 2021

Acute calcific or ossific tendinitis, a disease of unknown etiology, is caused by the deposition of hydroxyapatite crystals in the tendon, ligament, bursa, or joint capsule, earning the name Hydroxyapatite disease (HADD). HADD is most seen around shoulder joints, but other joints such as the spine, elbow, wrist, hand, hip, knee, ankle, and foot may be affected.[1] Tendinitis may be associated with tenosynovitis, inflammation of the fluid-filled synovium within the tendon sheath. Expansion of the tendon sheath due to synovitis and fluid accumulation results in bursitis, a fluid-filled synovial sac.

The presence of enthesopathy-associated tendinitis is not uncommon at the Achilles, quadriceps, and triceps insertions. However, this benign but limiting condition is rarely seen in the longus colli and is thus often misdiagnosed. Dr. Jamshid Tehranzadeh, Chief Radiologist at United Medical Imaging Healthcare (UMIH), and Dr. Arash David Tehranzadeh, Co-Director of Musculoskeletal Radiology at Cedar-Sinai Kerlan Jobe Institute, report a case of hydroxyapatite deposition disease with a rare manifestation of enthesopathy at the insertion site. The two collaborated to treat a 75-year-old woman with acute calcific tendinitis and bursitis of the longus colli. A tendinitis diagnosis is often made or confirmed by CT study. However, Drs. Tehranzadeh and David Tehranzadeh were able to confirm the diagnosis using plain radiography and MRI study. In this case, the presence of bursitis visible in the MRI facilitated the diagnosis of HADD.

Case Study: Enthesopathy-Associated Acute Calcific Tendinitis and Bursitis of Long Colli Tendon

A 75-year-old woman presented to the clinic with severe neck pain (acute cervicalgia) and severe left shoulder pain, which radiated to the left upper extremity. She reported that the pain began five days before her visit. The patient has a history of arthritis in her fingers and one knee. Her mother had a history of tendinitis of the shoulders, and her brothers and cousins had a history of carpal tunnel syndrome.

A plain radiograph of her cervical spine showed osteopenia, consistent with the osteopenia diagnosis she received two years after a DEXA scan. The radiograph revealed changes in cervical spondylosis such as disc narrowing, facet arthritis, and uncovertebral joint arthritis. Her mild spondylolisthesis of the C4 and C5 vertebral bodies, identified via radiograph, is assumed to be related to facet arthritis and ligamentous laxity. The most significant finding from the radiograph was an ossific density measuring 3.5mm at the inferior aspect of the anterior tubercle of the atlas associated with enthesopathy of the anterior cortex of the body of C2 (axis).

A cervical spine MRI performed the next day revealed that the ossific density located below the anterior tubercle of the atlas was accompanied by enthesopathy of the anterior cortex of the C2 vertebra (insertion site of longus colli tendon) and a pear-shaped fluid-filled bursa measuring 11x6x7mm anterior to the body of the C2 (axis) vertebra (Figure 1-5). Because of this finding, the patient was diagnosed with calcific (ossific) tendinitis and bursitis of the longus colli. Her otolaryngologist referred her to a pain management specialist for a steroid injection of the longus colli tendon. The steroid injection combined with oral use of hydrocodone bitartrate, acetaminophen, and ibuprofen, markedly improved her pain, which resolved a few days later. During her two-month follow-up visit, the patient reported that she was pain-free and doing well.

Clinical Implications of Rare Enthesopathy-Associated Hydroxyapatite

While the etiology of tendinitis and bursitis is unknown, repetitive trauma, ischemia, necrosis, and degenerative changes of the tendon may be responsible for inflammatory responses leading to calcific or ossific tendinitis (4). Enthesopathy, which signals an inflammatory response, is manifested by calcification, ossification, and fluffy new bone formation at the insertion site of the tendon. Enthesopathy associated with tendinitis is not uncommon in the Achilles tendon, quadriceps, and triceps insertions. However, enthesopathy associated with tendinitis of longus colli is rarely reported.

The longus colli is a paired muscle covering the anterior prevertebral area of the entire cervical spine and the first three upper thoracic spines bilaterally (Figure 6). It has three segments: superior, intermediate, and inferior. The superior segment originates from tubercles of the transverse processes of the C3-C5 vertebrae and inserts on the anterior tubercle of the atlas (C1). The Intermediate segment originates from the anterior surface of the bodies of C5-T3 and inserts on the anterior bodies of C2-C4 vertebrae. The inferior segment originates from the anterior surface of bodies of T1-T3 vertebrae and inserts on anterior transverse processes of C5-C6 vertebrae. Bilateral contraction of the longus colli causes flexion of the neck, and unilateral contraction of the longus colli contributes to contralateral rotation and ipsilateral neck lateral flexion.[2]

Drs. Tehranzadeh and David Tehranzadeh's 75-year-old patient does not fit the typical profile of a tendinitis patient as tendinitis is typically diagnosed in patients between 30-60 years. Acute tendinitis of longus colli is relatively rare but not as rare as the literature is presenting. In an epidemiologic study, this condition comprises 0.5 cases per 100 000 person-years.[3,4] However, this condition is often misdiagnosed as it may mimic other diseases with severe neck pain and stiffness, such as meningitis or retropharyngeal abscess.[5,6,7] Other clinical differential diagnoses for acute tendinitis of longus colli include disc protrusion, neoplasm, and traumatic fracture dislocation.[5] In rare cases, calcific tendinitis or bursitis of the longus colli may present as a cause of dysphagia and odynophagia.

Colella et al. describe a case of acute calcific tendinitis of longus colli presenting with dysphagia.[5] In their literature review, they report the most common presenting symptoms of longus colli tendinitis are severe neck pain (94%), limited range of motion (45%), and odynophagia (45%), stiff neck (42%), and dysphagia (27%). Although dysphagia and odynophagia often accompany each other, dysphagia is defined as difficulty swallowing, whereas odynophagia is when swallowing is painful. Other clinical presentations of longus colli tendinitis include sore throat (17%) and neck spasm (11%). Moreover, laboratory findings may indicate an increase in leukocytosis and inflammatory markers.[4]

Diagnosis of this case was ultimately made with plain radiograph and MRI. However, the gold standard for diagnosis is computed tomography (CT scan), which visibly shows even minor calcifications.[5] MRI tends to obscure low signal calcification, but fat-containing ossification shows a bright signal that is difficult to miss on an MRI scan. The presence of a fluid-filled bursa with a bright T2 fluid signal, occasionally associated with tendinitis, can facilitate diagnosis, as demonstrated by this case study (Figure 4).

Treatment for tendonitis is often conservative—in mild to moderate cases, NSAIDs are used, whereas corticosteroids and opioids are reserved for more severe cases.

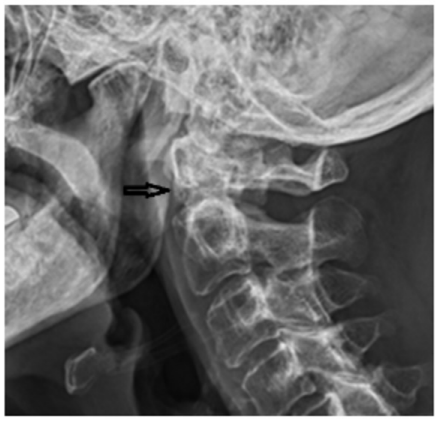

Figure 1. Ossific Tendinitis of Longus Coli: Lateral radiograph shows small ossific density below anterior tubercle of the atlas (arrow). There is enthesopathy of the anterior cortex of the axis (C2).

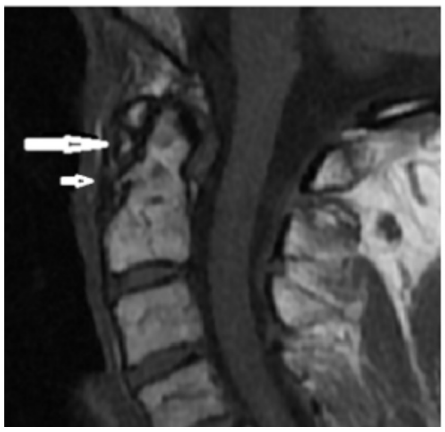

Figure 2. Ossific Tendinitis of Longus Coli: Sagittal T1WI Spin echo image shows small ossific density below anterior tubercle of the atlas (Long arrow). There is also an enthesophyte (Short arrow) noted at the anterior cortex of C2, which is another sign of tendinitis.

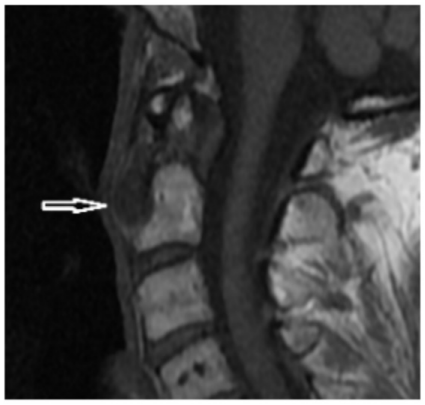

Figure 3. Ossific Tendinitis of Longus Coli: Sagittal T1WI Spin echo image shows a pear-shaped fluid-filled T1 dark signal bursa (arrow) below the anterior tubercle of the atlas and in front of the body of the C2 vertebra.

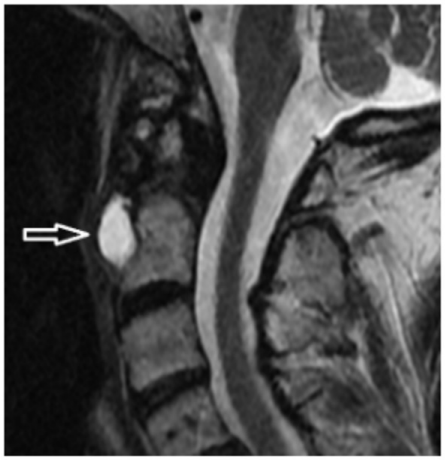

Figure 4. Ossific Tendinitis of Longus Coli: Sagittal T2WI Spin echo image shows a pear-shaped fluid-filled T2 bright signal bursa (arrow) below the anterior tubercle of atlas and in front of the body of the C2 vertebra.

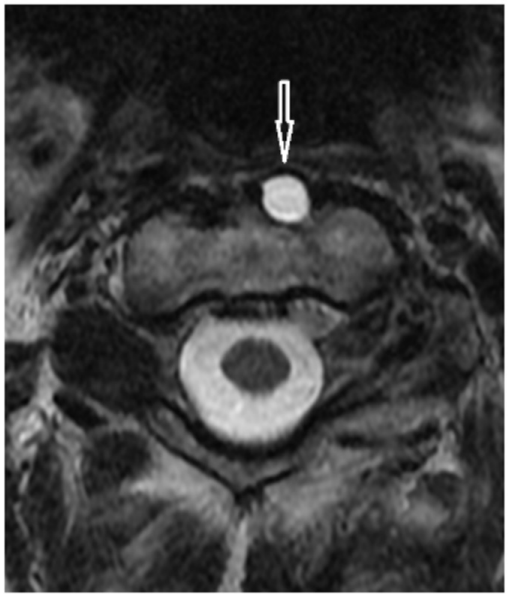

Figure 5. Ossific Tendinitis of Longus Coli: Axial T2WI Spin echo image shows a fluid-filled T2 bright signal bursa on the left paracentral space in front of the anterior body of C2 vertebra (arrow).

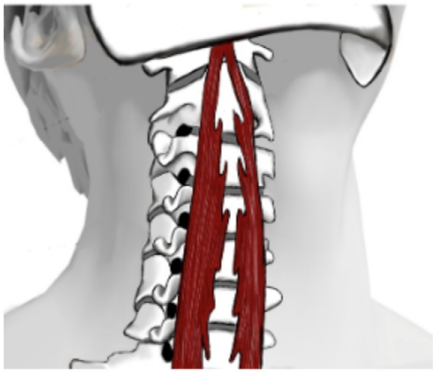

Figure 6. Normal Anatomy of Longus Colli Muscles

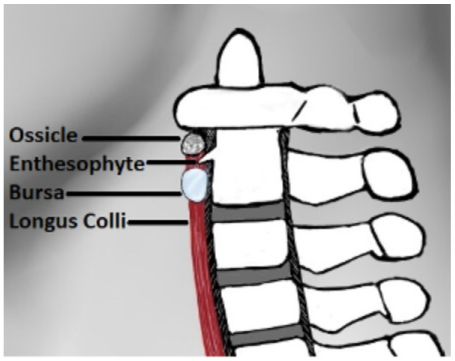

Figure 7. Ossific Tendinitis of Longus Colli: Sagittal Line drawing image shows a small ossific density below the anterior tubercle of the atlas (ossicle). There is also an enthesophyte noted at the anterior cortex of C2, which is another sign of tendinitis. The fluid-filled bursa is seen below the enthesophyte along the tendon of the longus colli.

United Medical Imaging Healthcare delivers high-quality comprehensive services to patients throughout Southern California.

To refer a patient to UMIH, call (310) 474-9800 ext. 106, or visit our website to download the patient referral form.

References

1. *Tehranzadeh J. Basic Musculoskeletal Imaging. 2nd ed. 2021, New York, NY. Mc Graw Hill*
2. *(Hons), A. R. B. S. (2021, October 6). Longus Colli Muscle. Kenhub. Retrieved October 14, 2021, from https://www.kenhub.com/en/library/anatomy/longus-colli-muscle*
3. *Horowitz G, Ben-Ari O, Brenner A, Fliss DM, Wasserzug O: Incidence of retropharyngeal calcific tendinitis (longus colli tendinitis) in the general population. Otolaryngol Head Neck Surg. 2013, Jun; 148(6):955-958. Doi:10.1177/*
4. *Raggio BS, Ficenec SC, Pou J and Moore B: Acute calcific tendonitis of the longus colli: Oschsner J. 18: 98-100. 2018.*
5. *Colella DM, Calderon Sandoval F, Powers DW, Patel N, and Sobrado J: A rare Cause of dysphagia to remember: Calcific Tendinitis of the longus Colli muscle: Case rep Gastroenterol 2016; 10: 755-759*
6. *Ring D, Vaccaro AR, Scuderi G, Pathria MN, Garfin SR: Acute calcific retropharyngeal tendinitis. Clinical presentation and pathological characterization. J Bone Joint Surg Am 1994;76: 1636–1642.*
7. *Omezzine S, Hafsa C, Lahmar I, Driss N, Hamza H: Calcific tendinitis of the longus colli: diagnosis by CT. Joint Bone Spine 2008;75: 90–91.*

Comment or add others with @